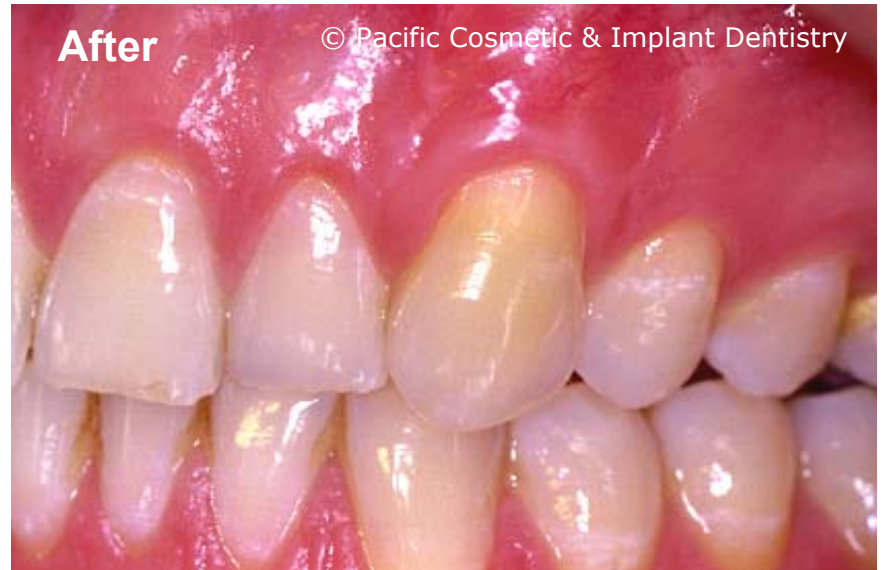
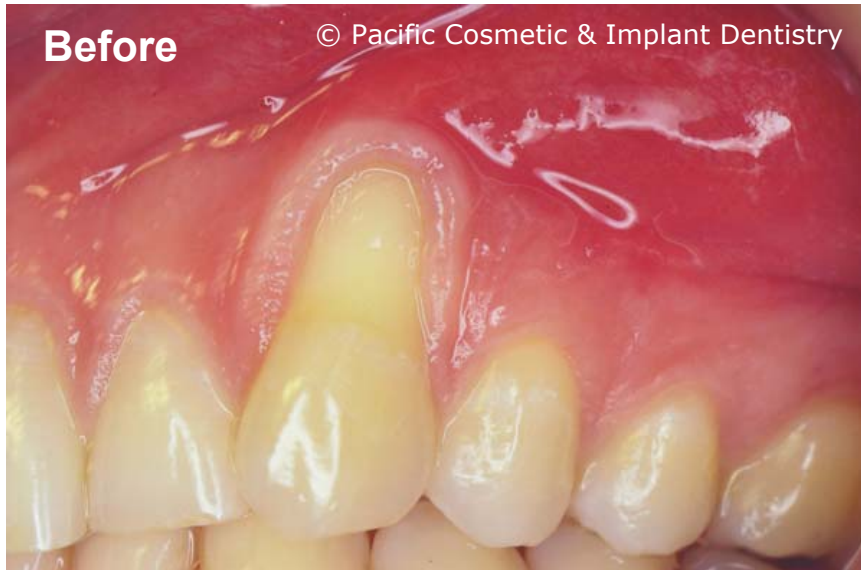
Correcting a Receding Gum Line



Correcting a Receding Gum Line

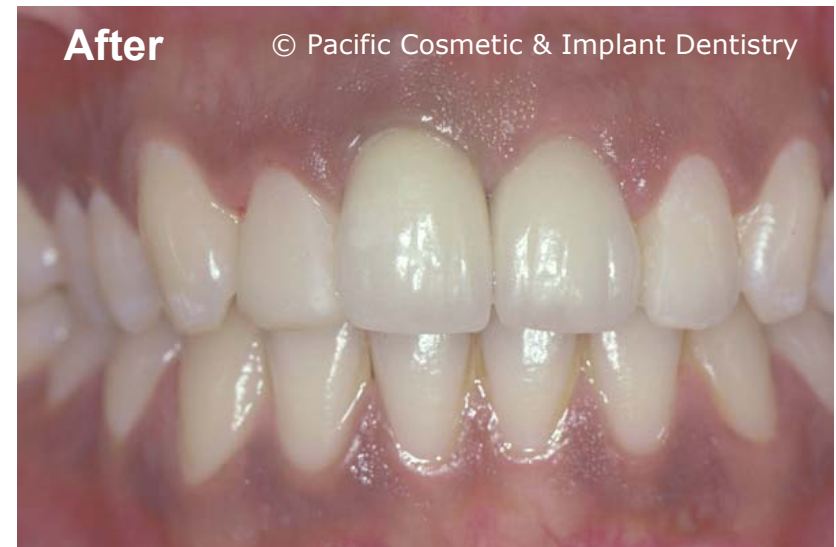
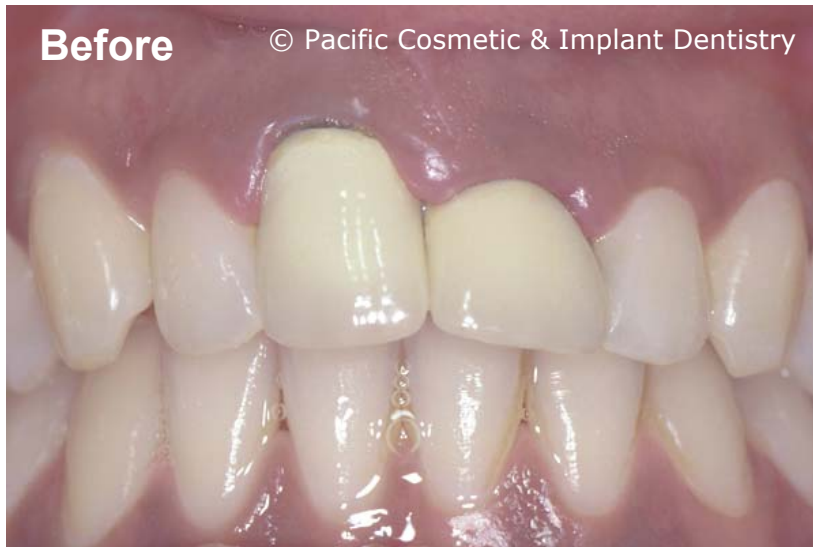Problem :

The patient's canine appeared too long as a result of a receding gum line

Solution :

The surrounding gums were surgically repositioned (downwards) to create gums around the canine for a more natural looking appearance.

Improving Poor Gum and Tooth Shape



Improving Poor Gum and Tooth Shape

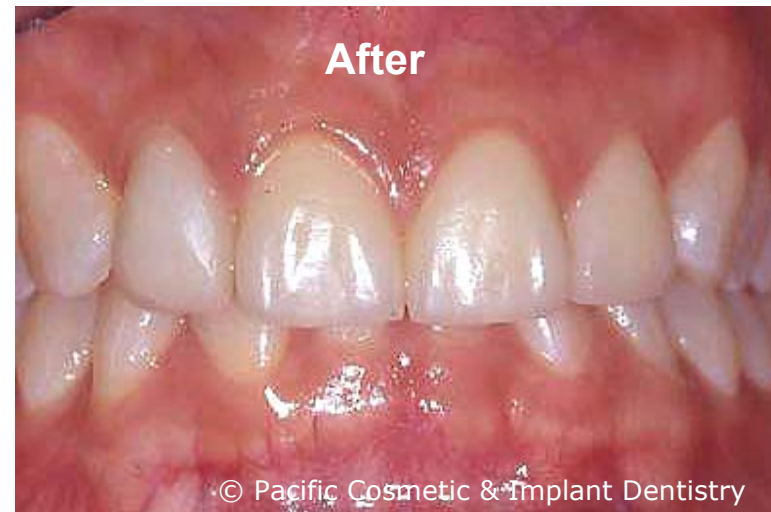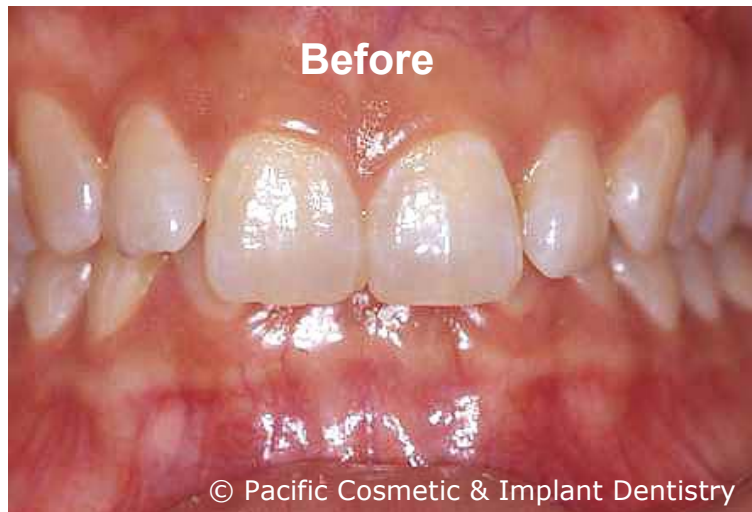
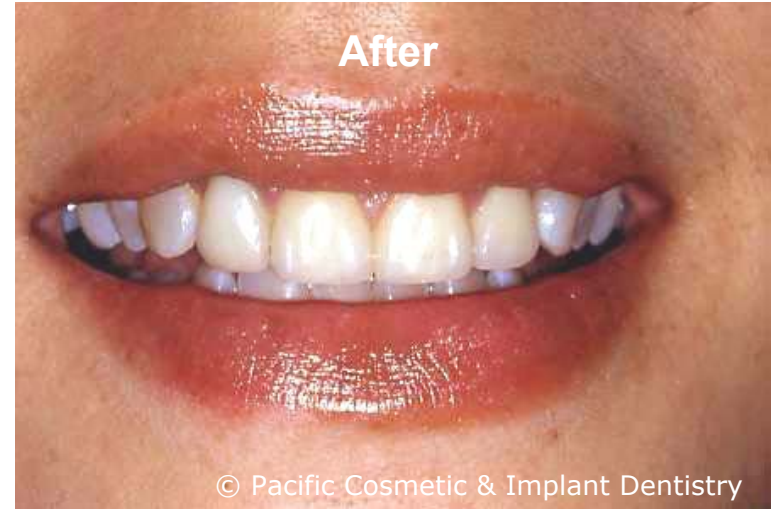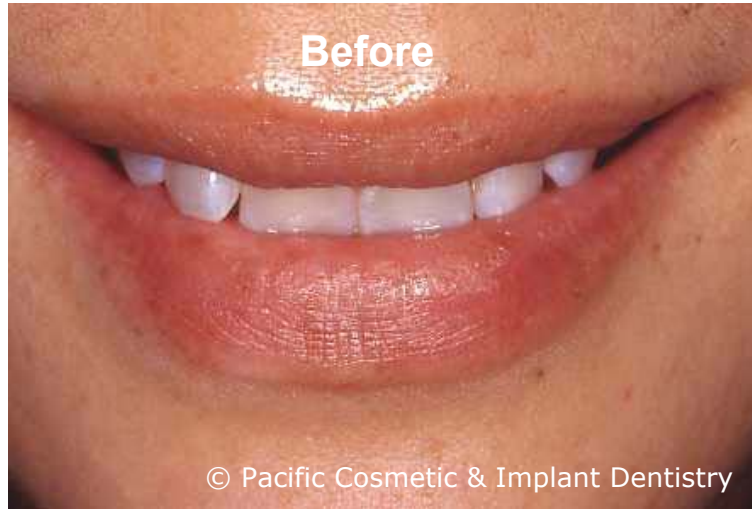
Problem :

The patient was unhappy with the uneven gum level and the opaque old crowns of her two upper front teeth.

Solution :

- 1) A Cosmetic gum recontouring procedure was carried out to balance the upper gum line.
- 2) The old opaque crowns were replaced with new porcelain crowns to create a more pleasing smile

Improving Tooth and Gum Contour



Improving Tooth and Gum Contour

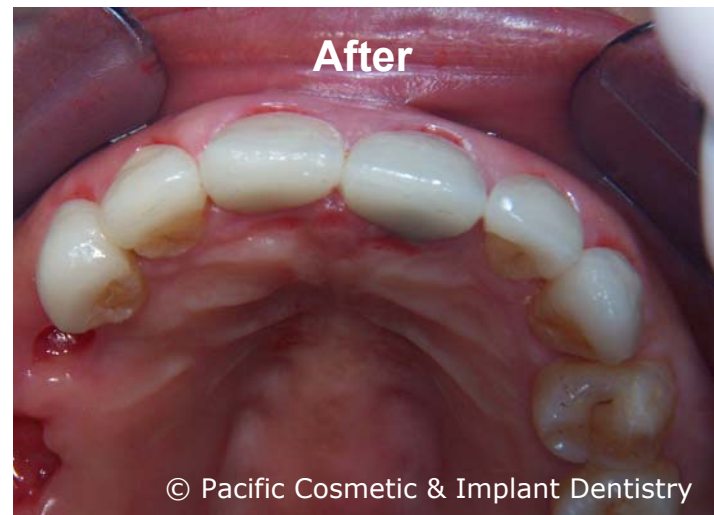
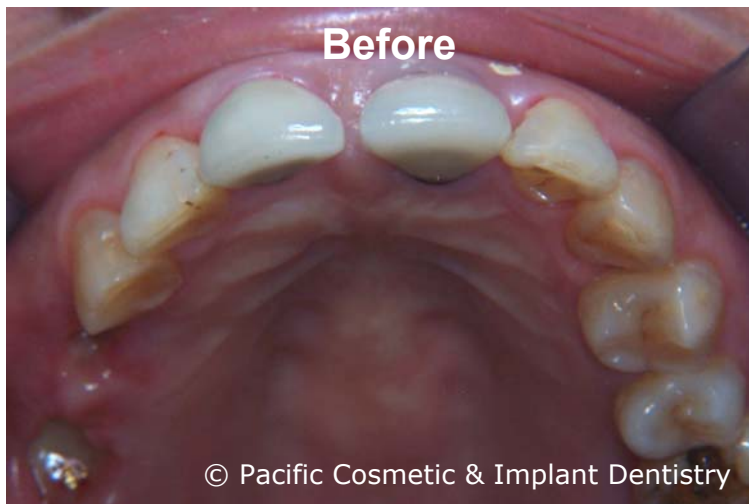
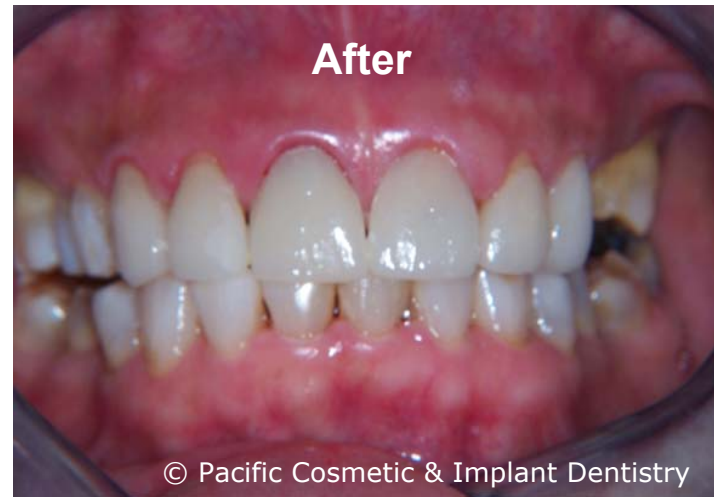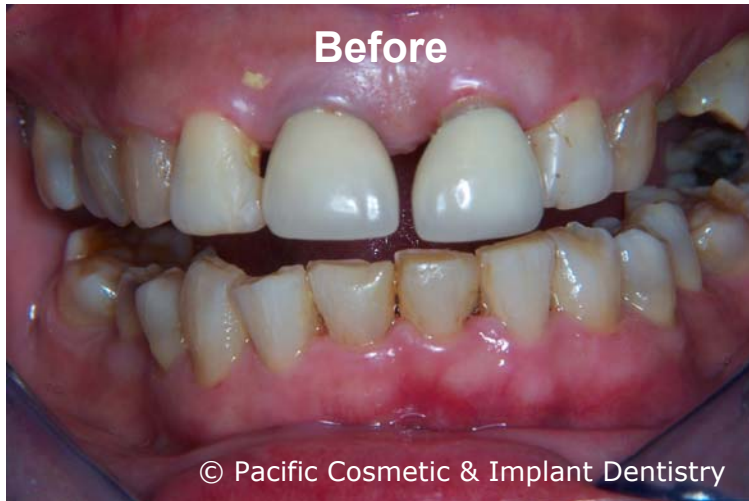Problem :

She was complaining of the presence of two very prominent upper front teeth, and an irregular upper gum line.

Solution :

- 1) Cosmetic gum recontouring of the four upper front teeth to provide an even and aesthetic gum line for subsequent veneer placement.
- 2) Porcelain veneers for four upper front teeth to correct the size and shape.

Closing Gaps and Improving Tooth Shape



Closing Gaps and Improving Tooth Shape

Problem:

This lady was unhappy with the appearance of her front teeth. Her main concerns were the spaces between her teeth, the opaque old crowns (caps) on her front teeth, and her “gummy smile”.

Solution :

- 1) Porcelain Crowns were done to close the gaps as well as to improve the colour and shape of all her upper front teeth. The teeth were also shortened.
- 2) Cosmetic gum recontouring was done to eliminate the gummy smile as well as to ensure correct length of the upper teeth.
- 3) Her teeth were bleached using in-office tooth whitening to remove the discolouration.